

Cephalometric Analysis of Maxillary and Mandibular Growth and Dento-Alveolar Change Part III

In two previous articles in the PCSO Bulletin's Faculty Files, we discussed the benefits and limitations of the conventional cephalometric morphological analysis (Part I). We have also discussed the use of the so-called "structural analysis" to examine general facial growth (Part II).

In this installment of Faculty Files, we will discuss how to analyze maxillary and mandibular growth and the associated dento-alveolar changes.

This part of the cephalometric analysis is used to evaluate two outcome factors:

1. To what extent maxillary and mandibular growth has contributed to the correction of a malocclusion
2. To what extent the correction was achieved through dento-alveolar change

This part of the analysis logically follows the evaluation of general facial growth that we have previously discussed. The most common technique used for

analyzing maxillary and mandibular growth has been a so-called "best fit" technique, in which the films are superimposed on structures that appear to remain unchanged during growth and treatment. In the maxilla, superimposition has been done on the nasal floor in what has been referred to as an ANS-PNS superimposition that usually is registered at ANS.¹ In the mandible, the films have been traditionally overlaid on the lower border of the mandible and registered at the chin. Both techniques are greatly flawed and can be improved by using a structural technique. The scientific basis for this method has been presented by Björk² and Björk and Skieller's studies^{3,4,5,8} of facial growth using so-called metallic implants. Perhaps a better term for the devices is "radiographic markers," so as not to confuse them with dental implants or orthodontic removable mini-implants used for anchorage.

When Björk analyzed facial growth in his untreated cases,² he found that both the maxilla and mandible undergo surface remodeling that in many cases is quite extensive. The result of this adaptation is that on the cranial-base superimposition, only a fraction of the change that has occurred during the period studied can be seen. There is a natural tendency for the soft tissues to mold the surface as an adaptive effort to maintain the inclination of the jaws in relation to the face—or, if you like, to the anterior and part of the median cranial base (nasion-sella).

Because of these remodeling changes, we need another and more reliable way of analyzing growth. Based on their findings using metallic radiographic markers, Björk and Skieller recommended instead using stable structures within the maxilla and mandible to superimpose on, so that this problem could be circumvented.⁸ The early studies using metallic markers that were embedded into the jaw bones markers also revealed that the anterior lower border of the mandible undergoes sometimes extensive apposition. In contrast, the posterior border often undergoes resorptive remodeling, causing a local change in the mandibular plane.

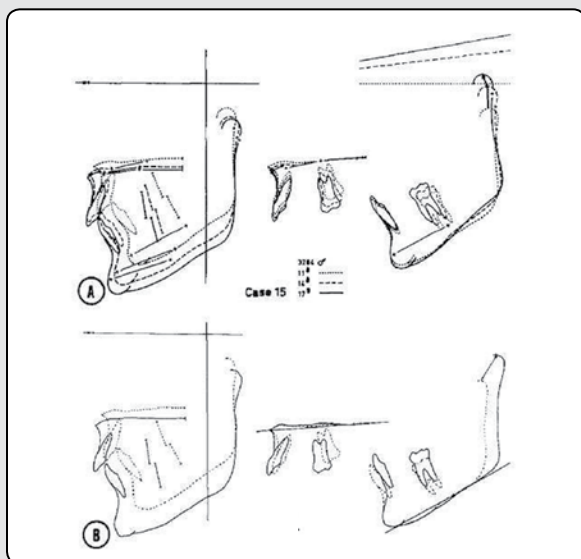


FIGURE 1

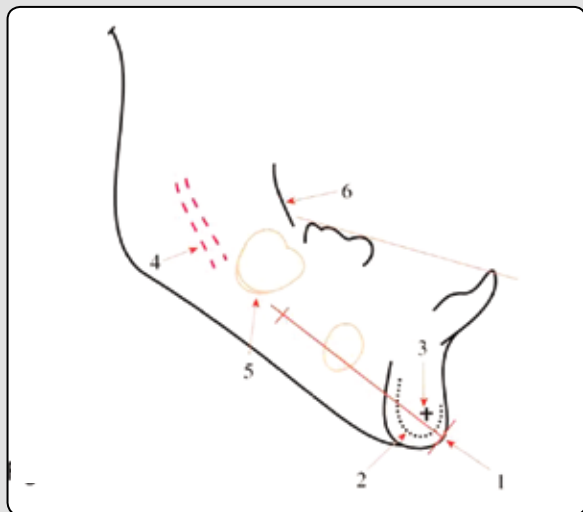


FIGURE 2

The clinical significance of this has been demonstrated by Isaacson et al,⁶ who retraced a number of illustrations from Björk and Skieller's article entitled "Facial development and tooth eruption."⁴ Isaacson et al. showed that in both the maxilla and mandible, there is a considerable difference between a best fit superimposition and superimposition on implants. One such case is seen in *Figure 1*. As Björk demonstrated, a result of these changes in some patients is that only half of the actual rotation of the mandible is seen on the general superimposition.

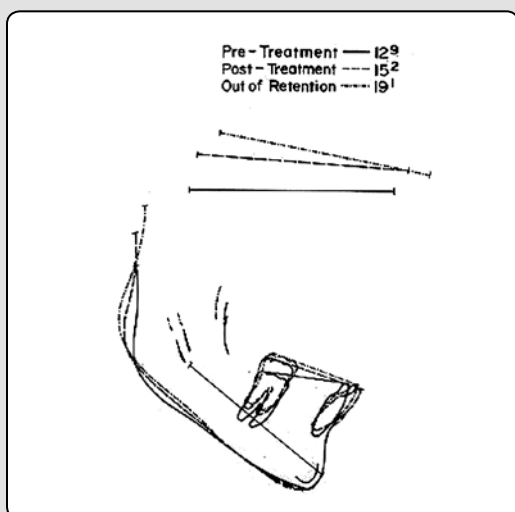


FIGURE 3

MANDIBULAR GROWTH AND TREATMENT ANALYSIS

In his studies of mandibular growth, Björk found that the following structures remained unchanged during growth⁷ (*Figure 2*):

- Anterior portion of the chin
- Inner lower border of mandibular symphysis
- Trabecular structures within the symphysis
- Mandibular canal
- Inferior portion of the contours of the molar germs before root development has started

Figure 3 illustrates a clinical example of the mandibular analysis in a treated patient. The superimpositions of three time points are made on the structures listed above. It can be seen that a considerable amount of remodeling of the lower border of the mandible has taken place over time.

The illustration also shows the degree of mandibular rotation relative to the anterior cranial base (NSL) by the change in inclination of the NSL lines between ages 12⁹, 15², and 19¹. The illustration additionally shows the amount of condylar growth that took place, in this case expressed at articulare, but also the mandibular occlusal plane change over time. The dento-alveolar changes such as the eruption path of the teeth and change in the inclination are also visualized in this superimposition.

As it can be seen in this example, a correct mandibular superimposition on stable structures in the mandible can yield a lot of valuable information about mandibular growth and dento-alveolar development. However, how accurate are measurements of the tooth movements (since they are transposed directly from the headfilm), and especially the molar movements (which are traced from a headfilm where double contours often are present)? From our clinical experience we all know that not only do we have a problem with molar position on the headfilm image, but we also have varying degrees of double contours from film to film. To get a more accurate estimate of where the molars are located, in his early works, Björk introduced⁷ the idea of using occlusal images of the dental arches in his illustrations (*Figure 4*). Using a complicated set-up with an image

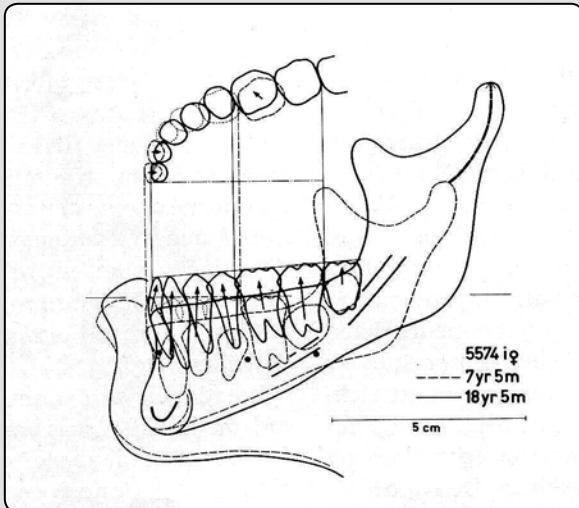


FIGURE 4

intensifier that enlarged the image of the study cast to about five times normal size and then tracing each tooth accurately, he could get a more precise idea of the actual tooth movements in all three dimensions. Today, a much simpler approach can be used to obtain the same information. At UCSF, we routinely use a photocopy of our study casts made with a conventional flatbed image scanner. To ensure the scan is not enlarged we place a ruler next to the model (Figure 5) so we can adjust for

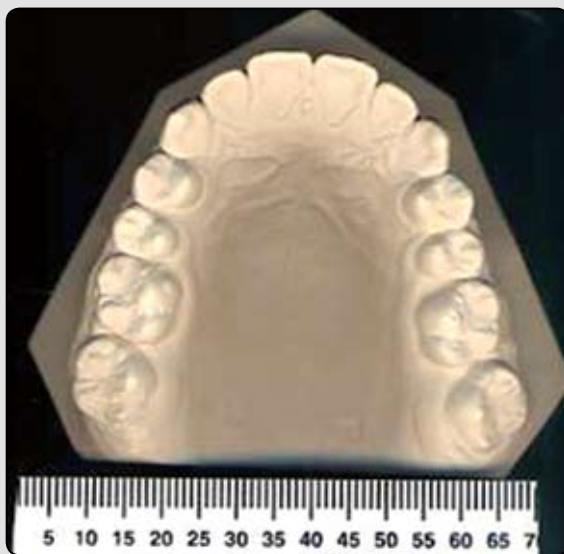

FIGURE 5

any magnification. Most scanner software and cephalometric analysis programs have the ability to adjust for magnification. In our case, we use the occlusograms in two different ways for analysis. On the mandibular superimposition shown in Figure 3, we initially trace only the incisors and the lower occlusal plane as seen on the headfilm. To place the molar correctly, we then measure the distance from the lower incisor (most prominent) to the mesial of the first molars on the occlusograms of the lower and upper casts, respectively. This measurement is then adjusted for magnification as needed and marked on the occlusal plane. Using a tooth template, we then trace the first molar aligned to the mesial marker. The axial inclination of the tooth is transferred from the headfilm to match the image on the film or the digital image.

If we are interested in the three-dimensional change of the dental arch, we can also benefit from using the occlusogram. Here we initially trace the mandibular structures, as described above, but once again we do not include the molars, as their positions will be determined by the location on the occlusogram. Figure 4 shows one such analysis and you will notice that only two stages are included. In this superimposition the two mandibular occlusal planes are bisected and a so-called occlusal plane bisector is constructed. At right angles to the incisors we then draw two perpendicular lines, and a line parallel to the occlusal plane bisector is constructed, along which the respective occlusograms are traced. This line will then serve as the dental arch midline for the two arches.

It is often advantageous to begin this process by tracing the upper model on the maxillary superimposition so as to determine the maxillary midline. This midline we place along the mid palatal raphe. It can then be transferred to the mandibular occlusogram after marking some of the teeth on the upper cast and bringing the upper and lower models into correct occlusion, thereby transferring these points to the lower model. However, this is only necessary in asymmetrical cases where one side may be askew. In most other instances we simply split the difference between the molars. Once the two occlusograms have been traced on the mandibular superimposition, perpendicular lines to the mesial of the molars on the occlusal image we have traced are traced. These lines are drawn down to the respective occlusal planes and thereby determine the correct molar position. This technique may seem cumbersome, but with a little practice it is not difficult or time-consuming,

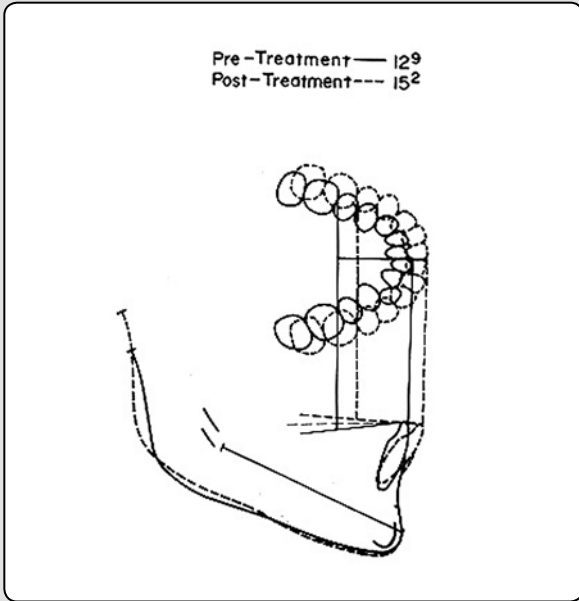


FIGURE 6

and provides a much more accurate representation of the three-dimensional dental changes. At UCSF, our residents use this technique routinely in their case presentations and they find that it provides good information as to the changes.

MAXILLARY GROWTH AND TREATMENT ANALYSIS

Analysis of maxillary and treatment change has routinely been done by using a “best fit” approach. Due to the difficulty in recognizing structures in the maxilla that remain unchanged during growth, it is only recently that a more accurate approach has been developed. Once again Björk,⁵ based on his implant studies, came up with a possible solution to the problem: the lack of a reliable superimposition. First, his previous studies had shown that when he placed metallic markers in the anterior outline of the zygomatic process of the maxilla, these markers were not lost, but remained in place over time. In a subsequent study of maxillary growth which included 21 boys followed from age 7 to 21, Björk and Skieller⁴ had found that the orbital floor undergoes bony apposition, whereas the nasal floor has resorptive remodeling over time. When they precisely measured these changes they found that the ratio between orbital floor apposition and nasal floor

resorption on average was 3:2. Using this information, we have since developed a “structural” superimposition for the maxilla.⁹ Maxillary superimposition on stable structures has been compared to best and fit and implant superimposition and the results showed that by using a best superimposition the average includes underestimating eruption of the incisors by about 50% and the molars by 30%.⁹ These findings have since been corroborated by a similar study by Doppel et al.¹⁰ So what can we do to get a more accurate estimate of the maxillary growth and treatment change? The approach we now use is based on the following technique developed at the recommendation of Björk in 1975. Using the information from his study of maxillary growth

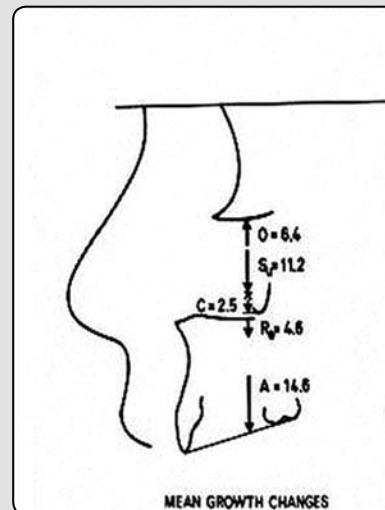


FIGURE 7

about the relationship between orbital apposition and nasal floor resorption, we align the headfilms, or tracings thereof, on the anterior outline of the zygomatic process of the maxilla. This is a similar location to the one used by Björk for his implants placement so we know this is an inactive area of the bone over time (Figure 5).

The second image is then moved up or down along this anterior outline until there is slightly more apposition on the orbital floor than resorption of the nasal floor. Figure 9 should serve as a guide—it shows a clinical example of a treated patient and includes three stages,

namely pre- and post-treatment and out of retention. Notice how growth in length is expressed at PNS and that the nasal floor was lowered relative to the superimposition, and more so anteriorly than posteriorly. The illustration also shows the tooth movements and change in the upper occlusal plane. The molar changes are corrected with the direct measurement from the occlusogram of the upper dental arch. The nasion-sella lines that were transferred from the individual headfilms

Whereas the mandibular analysis, using the stable structures as references, has gained a lot of users in recent years, and is accepted by the American Board of Orthodontics, the maxillary analysis still has not become the norm. Hopefully the Board will accept this approach to maxillary analysis as the gold standard in the near future, as it provides much more reliable analysis of the changes.

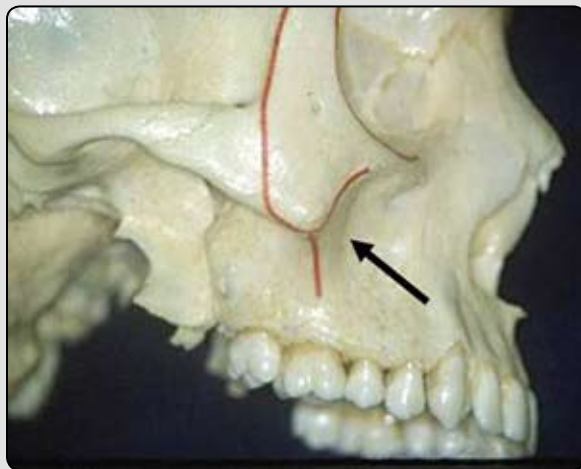


FIGURE 8

show that some degree of anterior or counterclockwise rotation of the maxilla took place during treatment and retention. In cases where we want to analyze the maxillary dento-alveolar changes, we include an occlusogram of the upper dental arch similar to what was done in the mandibular analysis. *Figure 7* shows the same patient's treatment analysis seen in *Figure 6*, but here we have only included two stages: pre- and post-treatment. The reason is that we have to arrange the respective occlusograms in relation to an occlusal plane bisector, so that only two time points can be included (as explained above).

It should be noted that the validity of the maxillary growth and treatment analysis with the structural technique is greatly dependent on good headfilms with clear images of the structures used in the superimposition. It is also important that the extent of double contour of the structures, in particular the zygomatic process, is limited and similar from film to film.

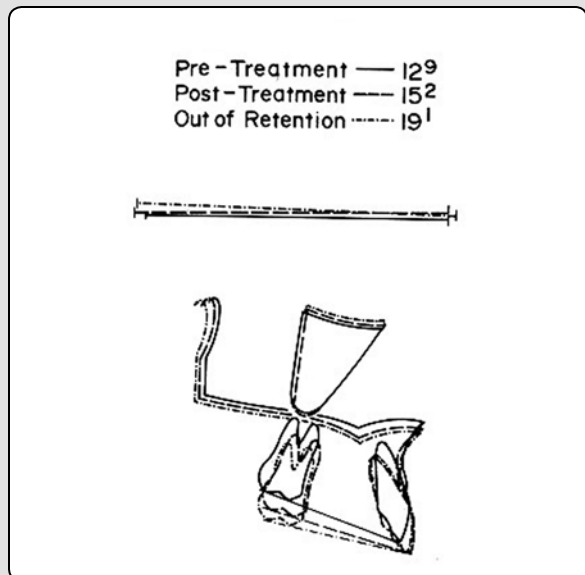


FIGURE 9

CONCLUSION

In Parts II and III of this series on cephalometric analysis, we have explained the technique for analyzing facial growth and the associated dental changes based on the conventional headfilm as if it was still the standard today. It should be noted, though, that digital images that are viewed on a computer screen are becoming more and more common. These digital images, however, can work just as well for the analysis described and they have the added advantage that no correction is needed for magnification, as the images are at zero magnification. Unfortunately, there are few programs available today that include the option for direct superimposition on the computer screen, so instead we suggest the following approach. Print out

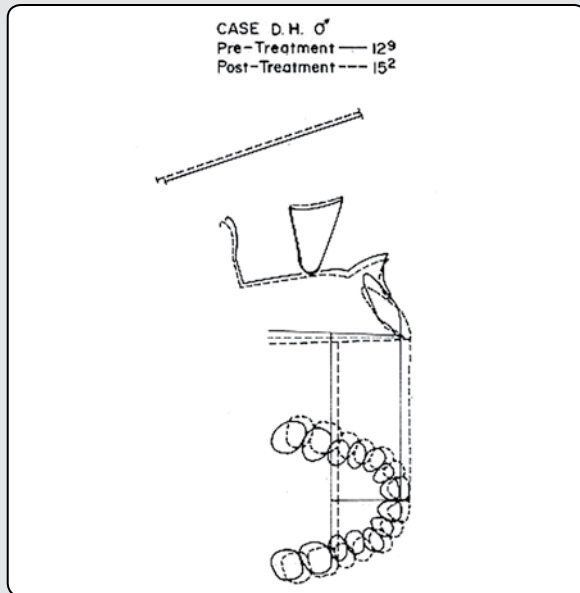


FIGURE 10

the images on transparencies, use these for superimposition, overlay them on the stable structures, and trace the images as we have described. The thoughtful clinician will appreciate that an accurate and meaningful cephalometric analysis can affect treatment outcomes.

REFERENCES

- 1 Ricketts RM. Foundation for cephalometric communication. *Am J Orthod.* 1960;46:330.
- 2 Björk A. Facial growth in man, studied with the aid of metallic implants. *Acta Odontol Scand.* 1955;13(1):9-34.
- 3 Björk A. The use of metallic implants in the study of facial growth in children: method and application. *Am. J. Phys. Anthropol.* 1968;29(2):243-254.
- 4 Björk A, Skieller V. Facial development and tooth eruption. An implant study at the age of puberty. *Am J Orthod.* 1972;62(4):339-383.
- 5 Björk A, Skieller V. Growth of the maxilla in three dimensions as revealed radiographically by the implant method. *Br J Orthod.* 1977;4(2):53-64.
- 6 Isaacson RJ, Worms RW, Speidel M. Measurement of tooth movement. *Am J Orthod.* 1976;70(3):290-303.
- 7 Björk A. Variations in the growth pattern of the human mandible: longitudinal radiographic study by the implant method. *J Dent Res.* 1963; 42(1):400-411.
- 8 Björk A, Skieller V. Normal and abnormal growth of the mandible. A synthesis of longitudinal cephalometric implant studies over a period of 25 years. *Eur. J. Orthod.* 1983;5(1):1-46.
- 9 Nielsen IL. Maxillary superimposition: a comparison of three methods for cephalometric evaluation of growth and treatment change. *Am J Orthod Dentofacial Orthop.* 1989;95(5):422-431.
- 10 Doppel DM, Damon WM, Joondeph DR, Little RM. An investigation of maxillary superimposition techniques using metallic implants. *Am J Orthod Dentofacial Orthop.* 1994;105(2):161-168.